

## Role of Surgical Excision in Persistent Koch's Cervical Lymphadenitis

Dr. Ravi M.S (General Surgery)<sup>1</sup>, Dr. A. Balamurugan M.S.,<sup>2</sup> (General Surgery)

<sup>1</sup>Department Of Surgery, Coimbatore Medical College And Hospital/The Tamil Nadu Dr. MGR Medical University, India

<sup>2</sup>Department Of Surgery, Coimbatore Medical College And Hospital/The Tamil Nadu Dr. MGR Medical University, India

---

**Abstract:** The study of enlargement of lymphnodes has always been fascinating. Its causes, presentation, and nature of occurrence has always been the area of research interest. Even in amidst of modern investigations, the clinical evaluation of lymphnode swelling still remains the corner stone. Amongst the lymphnode swellings in the neck, Koch's lesion amounts to be the major etiological factor of presentation. Of the 20 patients who underwent surgical excision of lymph nodes, 12 were cured. Among the 8 patients who were not cured, 2 developed recurrences, 2 Developed sinuses and 4 showed emergence of new lymph nodes due to co-morbid conditions like poor nutrition, diabetes mellitus and immunocompromised. Among the 20 patients who were administered CAT II ATT, 9 were not cured, 2 had persistent lymphadenitis. 4 developed cold abscess. 3 developed discharging sinuses due to poor response to chemotherapy alone. So they need for excision of neck node for disease free status. It was concluded in this study that, surgical excision of involved cervical lymphnodes might be a better option than chemotherapy alone.

**Keywords:** ATT, Cervical lymphadenitis, Koch's lesion, lymphnodes, Tuberculosis

---

### I. Introduction

The head and neck region remains part of intricate anatomical region with its structures carrying out highly complex and important physiological functions. Study of diseases in this complex region has always remained interesting especially the study of enlargement of lymphnodes. Its causes, presentation, and nature of occurrence is a fascinating work and involved not only the interest of the surgeon but also of other specialities. In spite of the special interest shown in the assessment of the lymphnode swelling by various specialities, Clinical evaluation of lymphnode swelling remains the corner stone for correct assessment of the disease pattern.

Surprisingly there are about 800 lymphnodes in our body and about 300 nodes are present in the head and neck region. Enlargement of lymphnodes occur in a variety of conditions ranging from simple reactive hyperplasia, secondary to infection in the draining area, to evidence of secondary malignant deposits and sometimes even malignancy occurring in lymphnodes itself.

Amongst the lymphnode swellings in the neck, Koch's lesion amounts to be the major etiological factor of presentation. Apart from evolving the diagnosis of the disease, in treatment part mere anti tuberculosis therapy alone is not sufficient to cure the disease. Our study shows the importance and the definite measures of absolute cure rate and disease free status obtained by surgical excision.

### II. Aims Of The Study

1. To evaluate the role of surgical excision in persistent Koch's cervical Lymphadenitis
2. To emphasize importance of surgical excision as a curative role in persistent Koch's cervical lymphadenitis compared to CAT II ATT alone.

### III. Materials And Methods

#### Study population:

Adult patients with persistent Koch's cervical adenitis after treatment with ATT category III attending the general surgery out patient and TB out patient department in Coimbatore medical college hospital were chosen for study

**Sample Size:** 40

**Study Period:** 2 years (2008 to 2010)

**Study Design:** analytical study

**Parameter Analysed:**

Patients with persistent Koch's cervical adenitis after treatment with ATT category III were

split into two study populations comprising 20 patients each :

(a) one population was subjected to surgical excision of lymph nodes.

(b) Second population was subjected to category II ATT

These patients were followed up for a period of 1 year. During the course of 1 year, patients in study population were categorized

**As (i)** cured (i.e. With no recurrence or complications)

**or (ii)** not cured (i.e. With recurrence or complications like sinus or fistula).

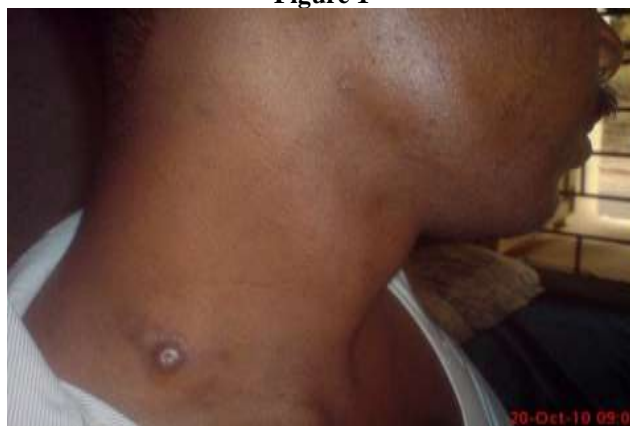Patients in study population (b) were categorized as cured (i.e. nodes disappeared) or not cured (i.e. nodes persistent). These two populations were analysed and subjected to a test of significance which tested whether surgical excision was superior to cat II ATT.

**Study protocol:** All adult patients attending surgery in CMCH from all 6 units with chronic cervical lymphadenitis (duration > 3 months) were subjected to FNAC, if FNAC revealed Koch's adenitis, the seriousness of the illness was analysed. If the general condition was found to be good, they were included in the study. The rest were excluded.

These patients were subjected to sputum microscopy for acid fast bacillus and to a chest radiograph. If either revealed Pulmonary Tuberculosis, these patients were excluded from the study. The rest were referred to the department of Tuberculosis in CMCH where they were administered cat III ATT for 6 months. The nodal status was assessed for persistence or disappearance. If the nodes disappeared, these patients were excluded from the study. The rest were subjected to either surgical excision of lymph nodes or category II ATT and analysed.

#### **Patient Developing Sinus After Node Excision**

**Figure 1**



Surgical excision of the lymph nodes was carried out on 20 patients after getting informed written consent for surgery and anaesthesia as well as a separate consent form for inclusion in the study. Surgery was performed under general anaesthesia under due supervision. Enlarged cervical lymph nodes were excised and sent for HPE which revealed caseating granuloma in all cases. Patients were discharged on the 5<sup>th</sup> postoperative day after assessing the presence of complications. Sutures were removed on 7<sup>th</sup> postoperative day. These patients were followed up for a period of 1 year.

20 patients were administered cat II ATT and followed up for a period of 1 year.

#### **Inclusion criteria:**

(1) Adult patients with Koch's adenitis > 3 months

#### **Exclusion criteria:**

1. Non- Koch's chronic cervical lymphadenitis
2. Seriously ill Koch's cervical adenitis
3. Koch's cervical adenitis with features of pulmonary tuberculosis
4. Cured Koch's cervical adenitis after treatment with cat III ATT for 6 months.

#### **Limitations of the study**

Follow-up was the major limiting factor. For effective follow-up, each patient was contacted either through mobile phone or postal address.

**IV. Observations**

Observations:

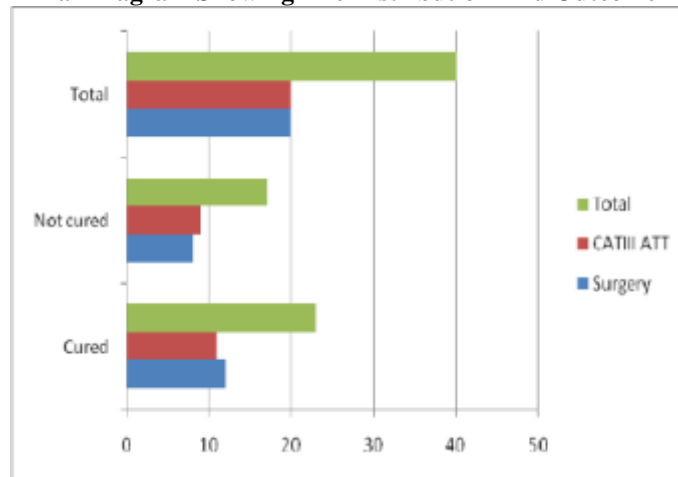
**Table 1**

Procedure	Cured	not cured	Total
Surgical excision	12	8	20

**Table 2**

Procedure	Cured	not cured	Total
Surgical excision	11	9	20

**Bar Diagram Showing The Distribution And Outcome**



**V. Discussion**

The surgery in Koch's cervical lymphadenitis is not advisable as a first line of management. 40 adult patients OPD in CMCH from unit 1 to 6 from the year 2008 to 2010, with features of persistent Koch's cervical lymphadenitis after ATT administration were analysed. They were classified into the populations (each with 20 patients) on random basis. One population was subjected to surgical excision and another to category II ATT. They were followed-up for a period of one year. Complications were analysed during and after the period of 1 year. Of the 20 patients who underwent surgical excision of lymph nodes, 12 were cured. Among the 8 patients who were not cured, 2 developed recurrences, 2 developed sinuses and 4 showed emergence of new lymph nodes due to co-morbid conditions like poor nutrition, diabetes mellitus and immunocompromised. Among the 20 patients who were administered cat II ATT, 9 were not cured, 2 had persistent lymphadenitis. 4 developed cold abscess. 3 developed discharging sinuses due to poor response to chemotherapy alone. So they need for excision of neck node for disease free status.

These results were subjected to a chi square test of significance, based on a 2x2 table with degree of freedom 4. Null Hypothesis was assumed that there was no significant difference between surgical excision and cat II ATT. Alternate Hypothesis was assumed that surgical excision of lymph nodes was superior to cat II ATT. At the end of the test of significance, it was hypothesized that there was no significant difference between surgical excision and cat II ATT ( $p < 0.05$ ).

**VI. Conclusion**

Cervical nodal TB is a common entity. The primary mode of management is to administer either cat I ATT or cat III ATT depending on whether the patients are seriously ill or not respectively. Treatment failure with either of these puts the patients in cat II ATT. The role of surgical excision of persistent Koch's cervical lymphadenitis even after ATT had been emphasized, as this only gives total cure to the disease. Eradication of residual Koch's lesion is achieved only in surgical management, apart from providing the cosmetic effect in patient with persistent Koch's cervical lymphadenitis even after ATT. Patient need not to be in prolonged and different categories of ATT. Hence, surgical excision of involved cervical lymph nodes might be a better option than chemotherapy alone.

**References**

- [1]. Attah EB. Peripheral lymphadenopathy in Nigeria. Trop Geogr Med. 1974 Sept; 26(3): 257-60.
- [2]. Cheesman AD. Pharynx, Larynx and Neck. Chapter-52 in: Bailey Love's Short Practice of Surgery, 24th Edition, Mann. Charles V, Russell RCG, William Norman S, Spain: ELBS with Chapman & Hall: 2004. 773.
- [3]. Farhi DC, Wells ST, Sigel RJ. Syphilitic lymphadenopathy – Histology

- [4]. and human immunodeficiency virus status. *Am. J. Clin Pathol.* 1999 Sept; 112(3): 330-4.
- [5]. Patten Bradley. Development of circulatory system. Chapter-19, in
- [6]. *Human Embryology*, 2nd Edition, New York: McGraw Hill; 1953. 608.
- [7]. Williams, Peter L et al. The lymphatic system. Chapter 393, in: *Grey's Anatomy*. 37th Edition, England; Churchill Livingstone; 1989. 821.
- [8]. Sahana SN. Lymphatic of head in neck. Chapter-1, in Sahana's human anatomy (Descriptive and Applied), Vol. II, 1st Edition. Calcutta: Ankur Publication; 1994. 179.
- [9]. Michael H Ross, Lynn J Romrel. Lymphatic System. Chapter-13. In: *Histology of Text and Atlas*. 3rd Edn. Baltimore; Williams & Wilkins; 1995. 343.
- [10]. Richard S Snell. The Head and Neck. Chapter-11. In: *Clinical Anatomy for Medical Sciences*. 3rd Edn. Boston/ Toronto; Little Brown 7Co; 1986. P. 743.
- [11]. Schmid Geert, Schoenbein, John Ross Jr. Structure function relation in peripheral circulation. Chapter-6 in: Best & Taylor's *Physiological basis of medical practices*. 12th Edition, West John
- [12]. B; New Delhi: 1996. 116.
- [13]. Chakroborty P. "Spirochetes", Chapter-44. Miscellaneous pathogenic bacteria. Chapter-46, in: *A Textbook of Microbiology*, 1st Edition, Calcutta; New Central Book Agency; 1995. 351.
- [14]. Ananthnarayanan R, Jayaram CK Paniker. Mycobacterium-Tuberculosis. Chapter-39, in: *Textbook of Microbiology*, 5<sup>th</sup> Edition, Chennai; Orient Longman; 1996. 325.
- [15]. Jindal N, Devi B. Mycobacterial cervical lymphadenitis in childhood. *Indian J Med Sci.* 2003; 57: 12-5.
- [16]. Watt B, Raynes A, Harris Gillman. Mycobacterium. Chapter-18, in: *Mackie & McCartney Practical Medical Microbiology*, Colledge JG et al, 14th Edition, Singapore; Churchill Livingstone; 1996. 329-330